

# The DENTAL DIGEST



VOLUME 39

September, 1933

NUMBER 9

Roofless Dentures - - - - -	326
<i>L. A. Hawkes, D.D.S.</i>	
The Editor's Page - - - - -	329
Impacted Mandibular Third Molars: Classification and Modified Technique for Removal - - - - -	330
<i>Glenn J. Pell, D.D.S., F.A.C.D. and G. Thaddeus Gregory, D.D.S.</i>	
Letters to the Editor - - - - -	338-360
A Complete Full Denture Technique - - - - -	339
6. The Adjustment of the Tripod	
<i>C. J. Stansbery, D.D.S.</i>	
About Our Contributors - - - - -	343
Dental Economics: The Old Order and the New - - - - -	344
<i>Edward J. Ryan, B.S., D.D.S.</i>	
The Dental Scene - - - - -	358
Report of a Case of Salivary Calculus in Wharton's Duct - - - - -	359
<i>E. J. Mohn, D.D.S.</i>	

EDWARD J. RYAN, B. S., D. D. S., Editor

ETHEL H. DAVIS, A. B., Assistant Editor

An Oral Hygiene Publication.  
Published monthly on the fifteenth  
by Dental Digest, Inc.

Entered as second class matter at  
the Postoffice at Ashland, Ohio, un-  
der the Act of Congress, March 3,  
1879.

PUBLICATION OFFICES: 636 Orange  
St., Ashland, Ohio.

EXECUTIVE OFFICES: 1125 Wolfen-  
dale St., Pittsburgh, Pa.

Merwin B. Massol, Publisher;  
Lynn Allen Smith, Treasurer; As-  
sociates: J. J. Downes, J. W. Kauf-  
mann; W. Earle Craig, D.D.S.;  
R. C. Ketterer, Publication Man-  
ager.

Subscriptions should be sent to the  
Executive Offices, 1125 Wolfendale  
St., Pittsburgh, Pa.

Manuscripts and correspondence  
regarding editorial matters should  
be addressed to the editor at 708  
Church Street, Evanston, Ill.

Subscription rates, including  
postage:

\$2 per year in the United States,  
Alaska, Cuba, Guam, Hawaiian  
Islands, Mexico, Philippines, Porto  
Rico. To Canada, Great Britain  
and Continent, \$2.75; Australia,  
\$4.25. All other countries, \$2.75.  
Single copies, 25c.

## DISTRICT OFFICES:

Chicago: Peoples Gas Bldg.;  
W. B. Conant, Western Manager.

New York: 18 East 48th St.;  
Stuart M. Stanley, Eastern Man-  
ager.

St. Louis: Syndicate Trust Bldg.;  
A. D. McKinney, Southern Man-  
ager.

San Francisco: 155 Montgomery  
St.; Roger A. Johnstone, Pacific  
Coast Manager.

Los Angeles: 315 West 9th St.

Copyright, 1933  
by Dental Digest, Inc.

# IMPACTED MANDIBULAR THIRD MOLARS: CLASSIFICATION AND MODIFIED TECHNIQUE FOR REMOVAL

GLENN J. PELL, D.D.S., F.A.C.D.

and

G. THADDEUS GREGORY, D.D.S.

Indianapolis

**T**HE importance of a complete analysis of the probable difficulties to be encountered in the removal of impacted mandibular third molars cannot be too greatly stressed.

Those engaged in the specialized field of oral surgery and exodontia have learned by experience to analyze and classify these cases. The general practitioner, however, because he is less often called to operate on impactions, frequently begins an operation that is beyond his ability, or fails to recognize abnormalities that alter the technique of removal. Naturally this is detrimental to the dentist, who loses the confidence of his patient, and to the patient, who is subjected to the unnecessary discomfort of a prolonged and perhaps unsuccessful operation.

Our classification was first evolved several years ago to rationalize the teaching of this subject at the Indiana University School of Dentistry. It is our purpose in presenting this work to give to the general practitioner and the student a means of analyzing the potential anatomic problems involved preparatory to the removal of impacted mandibular third molars.

Fundamentally we do not offer much that is new. A study of third molars in relation to the ramus is advocated by Doctor Wilton W. Cogswell in his new book, *DENTAL ORAL SURGERY*. The diagnostic importance of the relation of the tooth to the long axis of the second molar was recognized years ago by Doctor George B. Winter. Many others have from time to time offered invaluable contributions to the never-ending study of this problem. We have merely united these various studies to make a more comprehensive analysis of the whole problem.

In the accompanying outline of the classification and the illustrations we attempt to grade impactions according to the relative difficulty that will be encountered in the effort of removal. The unknown quantity; i. e., individual peculiarities and idiosyncra-

sies, has naturally been disregarded. We believe that, if, in every case, the operator will by a careful study of properly made roentgenograms ascertain the relation of the tooth to the ramus; the depth of the tooth in bone; the position of the tooth in relation to the long axis of the second molar, and if he will make a careful examination for complicating abnormalities—then, he will be able to make an intelligent prognosis to his patient. By self-analysis he can determine whether or not his skill is sufficient to justify his undertaking the case. For example, a Class I, position A, mesio-angular impaction is comparatively easy; on the other hand, a Class III, position C, horizontal impaction will tax the ability of the best of operators.

## MODIFIED TECHNIQUE FOR THE REMOVAL OF IMPACTED MANDIBULAR THIRD MOLARS

The primary object in any form of surgery is to perform the operation successfully and as skillfully and as rapidly as possible with the minimum amount of trauma to contiguous tissues.

The removal of impacted mandibular third molars produces varying degrees of traumatic injury to the surrounding hard and soft tissues. In years past these operations were accompanied by extreme pain, swelling and trismus. In many cases more alarming symptoms developed, and occasionally necrosis, osteomyelitis or periostitis occurred.

Each year has seen the development of refinements in technique with a consequent decrease in unfavorable postoperative sequels. Incisions are made and tissues retracted in a manner to give the maximum access and at the same time prevent harmful pulling and tearing of the parts. Care is exercised in removing bone, and if burs are used, they are so handled as to prevent overheating. Crude, massive elevators have been replaced by smaller and more scientifically correct levers that do not injure adjacent

teeth and tissues. Briefly, a method that is widely used is as follows:

The occlusal of the tooth is exposed; bone is removed on the buccal to permit the introduction of a lever; then bone is removed on the distal to allow the tooth to be elevated back into the space and unlock the tooth. There is always a certain amount of guess work in this procedure. Many times after relief has been obtained and the tooth elevated, it is found that the tooth still binds on the distobuccal or disto-lingual. Then more bone must be chiseled away until the impaction is completely relieved. This method requires the removal of considerable bone.

Recently some men have advocated the splitting of teeth to facilitate removal. It is a reasonable deduction that a technique of removal which entirely eliminates the necessity of cutting away the bone in some cases, and materially reduces bone cutting in all cases will shorten the operating time and minimize trauma to surrounding tissues.

During the past two years we have been developing a modified splitting technique which we believe worthy of consideration:

1. The crown of the tooth is exposed in the usual manner, and sufficient bone is removed on the mesio-cervical of the third molar to permit the introduction of a small lever.

2. Then an engine chisel or a mallet and chisel are used to split off the distal portion of the tooth. The chisel is placed as nearly as possible in line with the long axis of the tooth, and usually in the buccal groove. Unless the chisel has been placed on gnarled enamel, a single blow will suffice. No effort is made to split the roots, although this sometimes occurs. It is sufficient to split the distal portion of the crown and whatever amount of the distal root that is included. If a mallet and chisel are used it is advisable to hold the mallet loosely between the thumb and forefinger. The blow necessary to split a tooth in line with the long axis is negligible; a sharp, not a hard blow is all

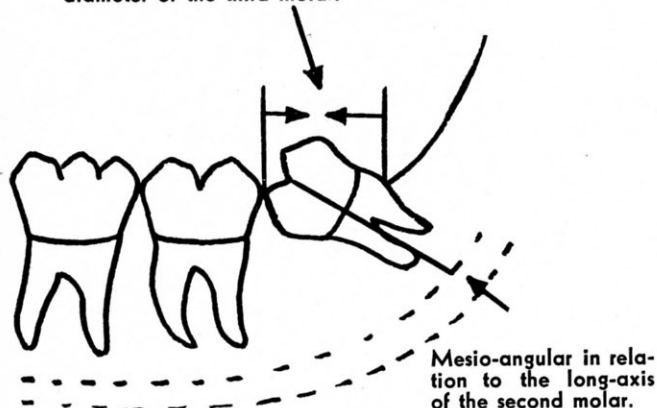
(text continued on page 338)

CLASS I

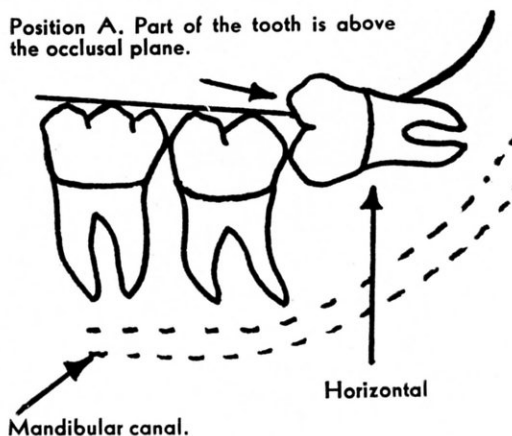
POSITIONS A B C

Class I impactions are those in which there is sufficient space between the ramus and the distal of the second molar for the accommodation of the mesio-distal diameter of the third molar.

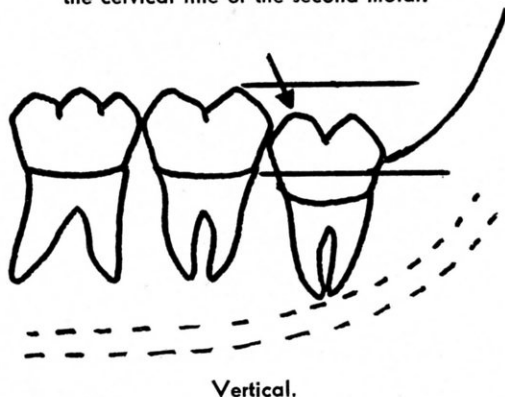
Class I. There is sufficient space for the accommodation of the mesio-distal diameter of the third molar.



Position A. Part of the tooth is above the occlusal plane.

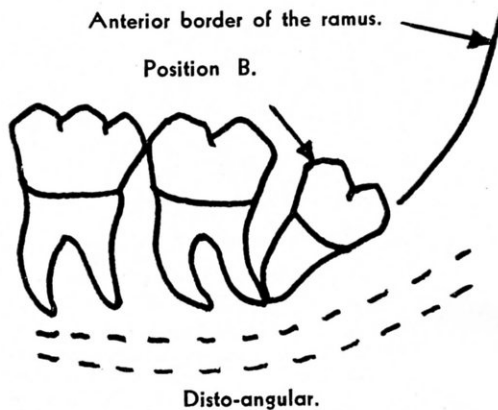


Position B. The highest portion of the tooth is between the occlusal plane and the cervical line of the second molar.

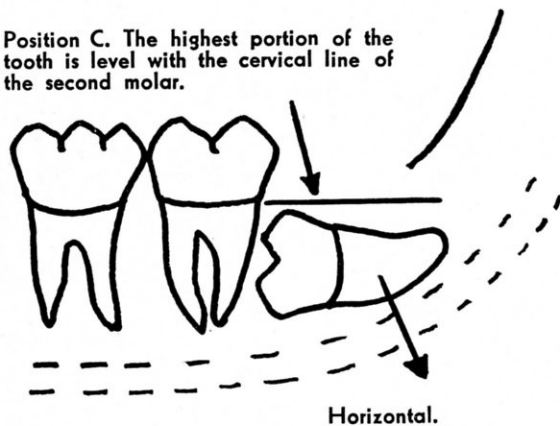


Anterior border of the ramus.

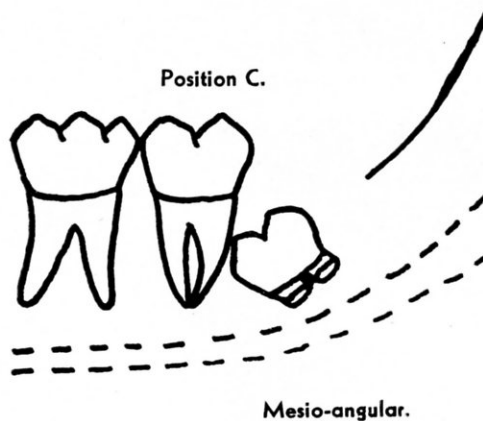
Position B.



Position C. The highest portion of the tooth is level with the cervical line of the second molar.



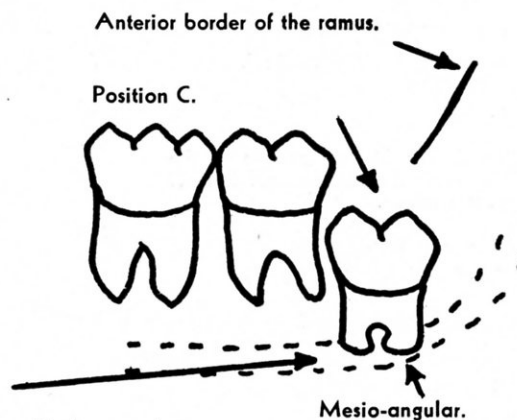
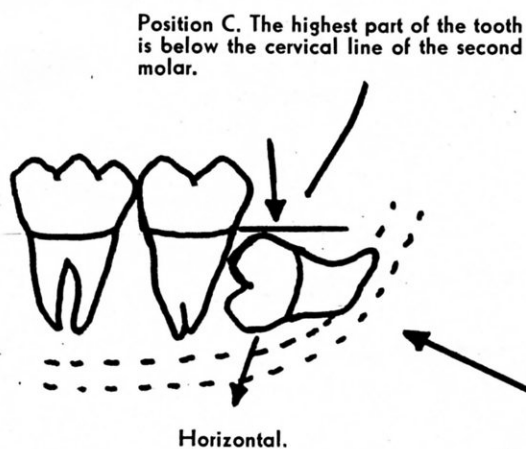
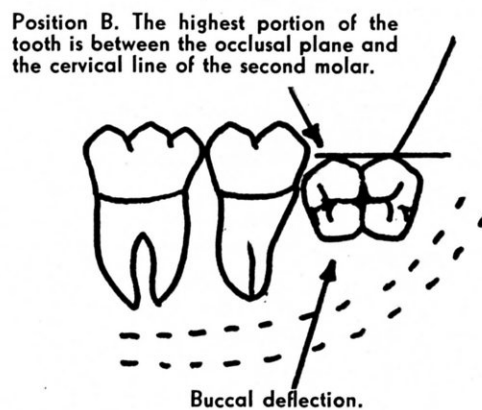
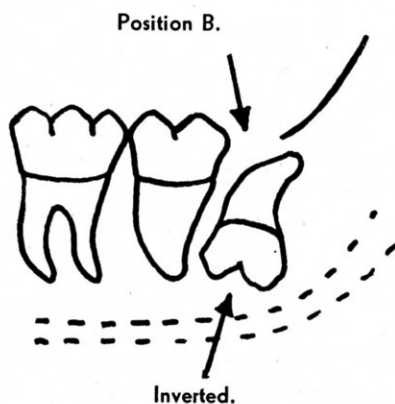
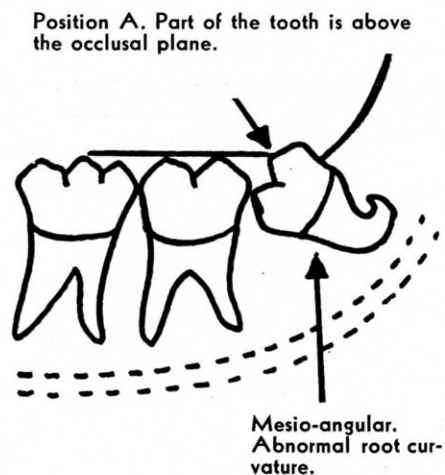
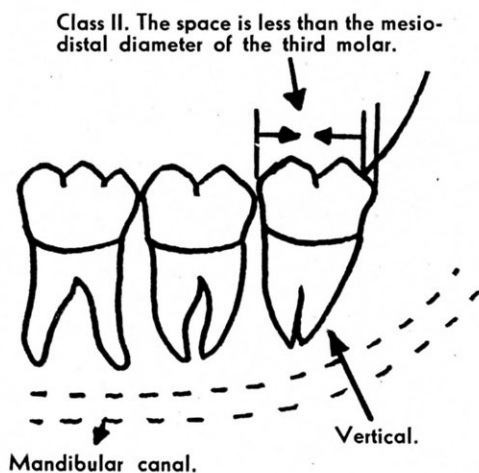
Position C.



## CLASS II

## POSITIONS A B C

Class II impactions are those in which the space between the distal of the second molar and the ramus of the mandible is less than the mesio-distal diameter of the third molar.



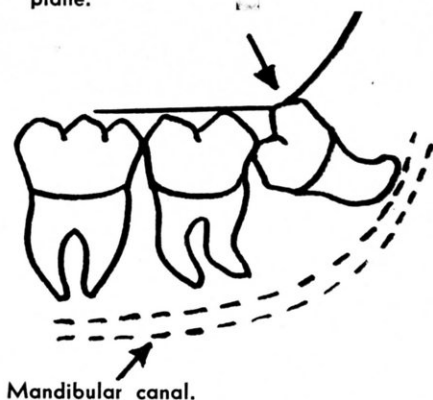
Note proximity to mandibular canal.

CLASS III

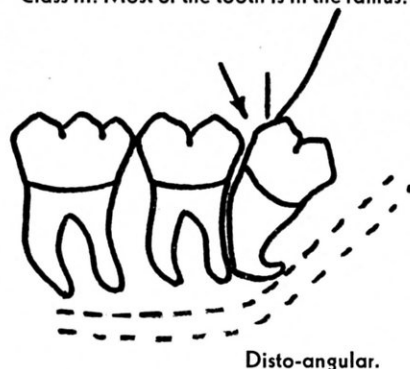
POSITIONS A B C

Class III impactions are those in which all or most of the third molar is in the ramus of the mandible.

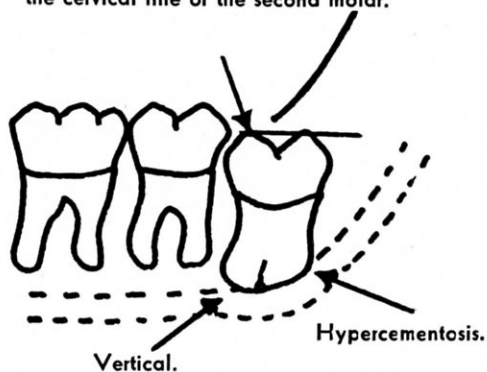
Position A. The highest portion of the third molar is on a level with the occlusal plane.



Class III. Most of the tooth is in the ramus.

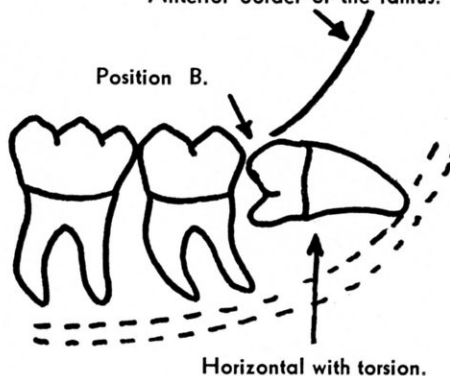


Position B. The highest portion of the tooth is between the occlusal plane and the cervical line of the second molar.



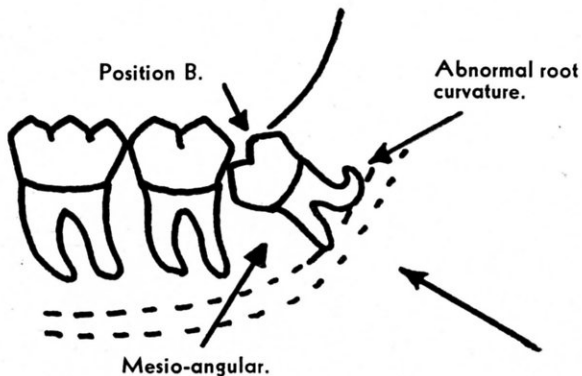
Anterior border of the ramus.

Position B.

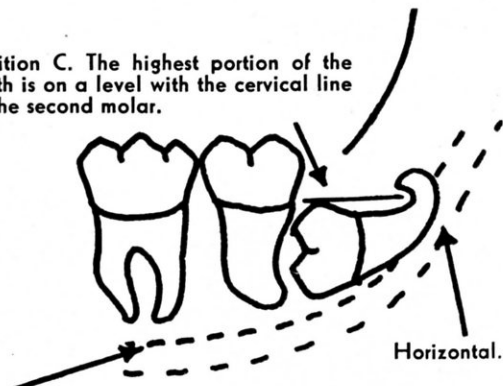


Position B.

Abnormal root curvature.



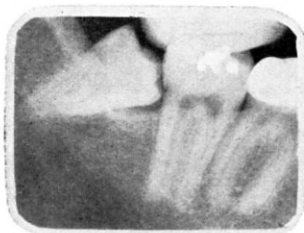
Position C. The highest portion of the tooth is on a level with the cervical line of the second molar.



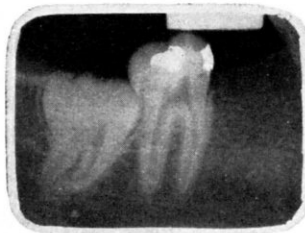Note proximity to mandibular canal.

## ROENTGENOGRAPHIC STUDY OF THE CLASSIFICATION

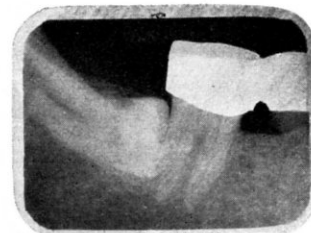
## Class I



1A  
Position A  
Mesio-angular

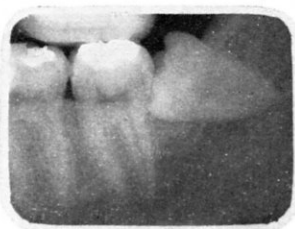

1B  
Position B  
Vertical

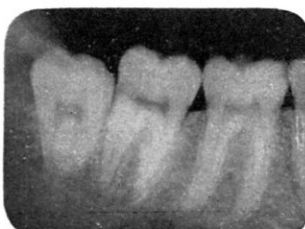

1C  
Position C  
Horizontal

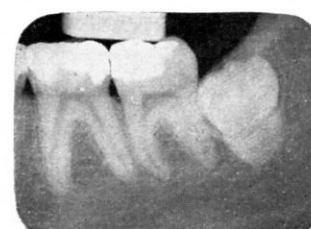## Class II



2A  
Position A  
Horizontal

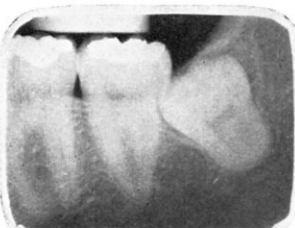

2B  
Position B  
Vertical

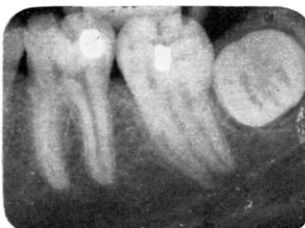

2C  
Position C  
Vertical with lingual deflection

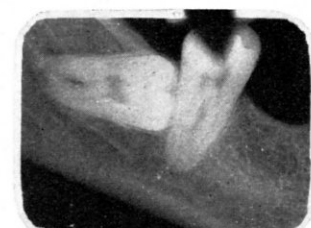## Class III



3-B  
Position B—Mesio-angular.  
Note relationship to mandibular canal



3B  
Position B  
Complete lingual deflection



3C  
Position C  
Note relationship to mandibular canal

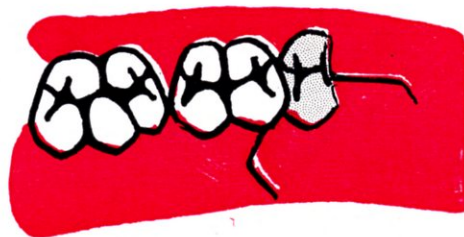

TECHNIQUE FOR THE REMOVAL OF A LOWER THIRD MOLAR  
CLASS II                      POSITION A                      MESIO-ANGULAR

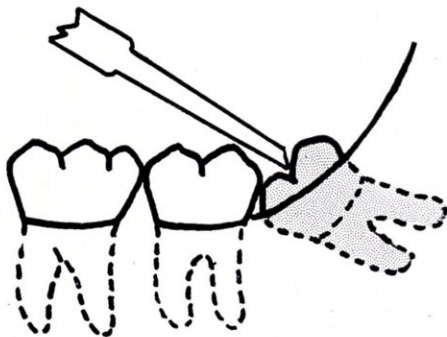
Buccal view showing clinical appearance of the case and the buccal incision.



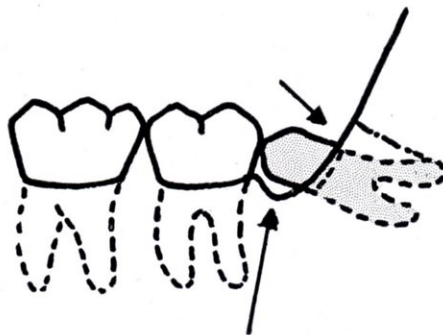
Occlusal view showing the incisions.



Chisel in place to split the distal portion of the tooth. (An engine chisel or a mallet and chisel may be used.)



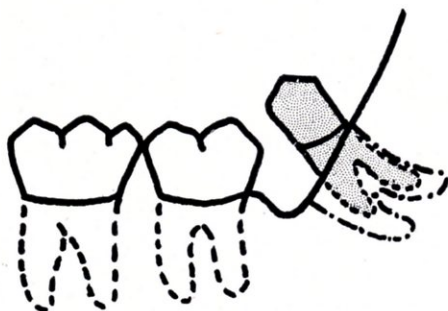
Distal portion of the tooth split and removed. Ample space is provided into which the remainder of the tooth may be moved.




To split a tooth it is advisable to hold the mallet loosely between the thumb and forefinger. A sharp, rather than a hard blow is all that is needed.

Sufficient bone chiseled away on the buccal to permit the introduction of a small lever.

The tooth has been turned into the space provided.

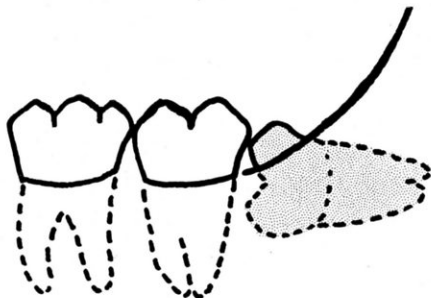


Incisions closed.

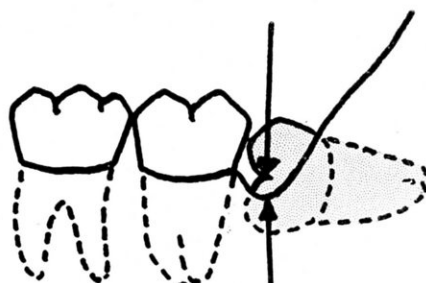


TECHNIQUE FOR THE REMOVAL OF A LOWER THIRD MOLAR  
 CLASS II                      POSITION B                      HORIZONTAL

Outline drawing of the case.

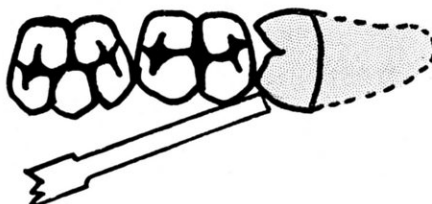


Point of application of the chisel to split upper portion of the tooth.




Sufficient bone removed on the buccal to expose the buccal groove.

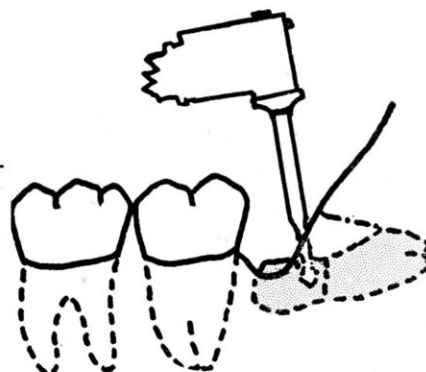
Occlusal view showing chisel in position to split the tooth



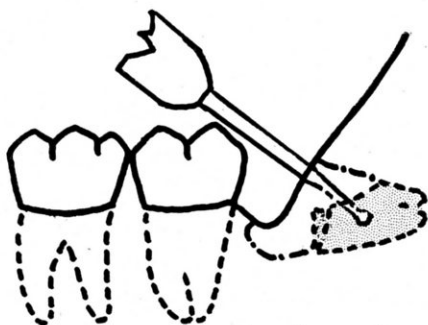
Upper portion of the tooth split and removed.



Spear-point or bi-bevel drill separating the remaining portion of the crown from the root.

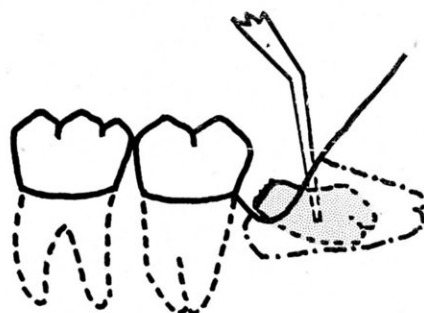


Drilling a hole in the root for the insertion of a lever.



Crown removed.

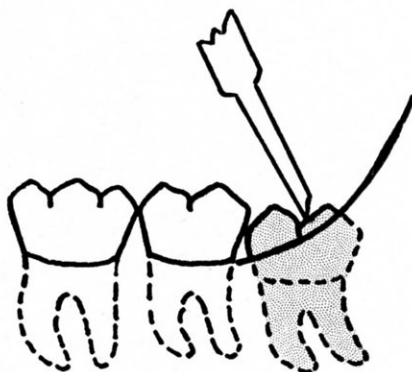
Lever in place and the root brought forward into the space provided.



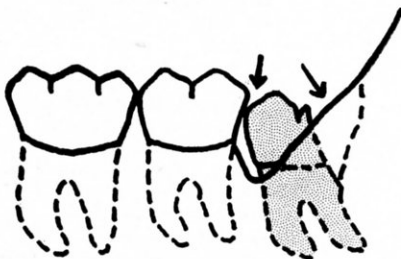


# TECHNIQUE FOR THE REMOVAL OF A LOWER THIRD MOLAR CLASS II POSITION B VERTICAL

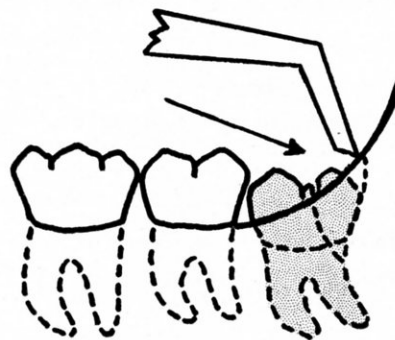
Chisel in place to split distal portion of the tooth.



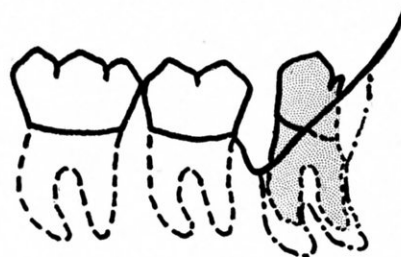
Split portion removed. Sufficient bone removed on the buccal to permit the introduction of a small lever.



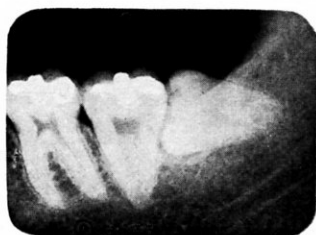Distal portion split. Chisel in place to remove sufficient bone on the distal to permit removal of the split piece.



Tooth turned back and up into the space provided.

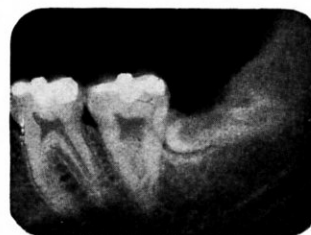

## ROENTGENOGRAMS DEMONSTRATING THE REMOVAL OF A THIRD MOLAR



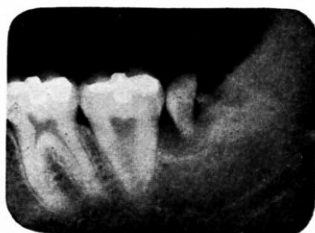7-B (a)

Class II  
Position A  
Horizontal



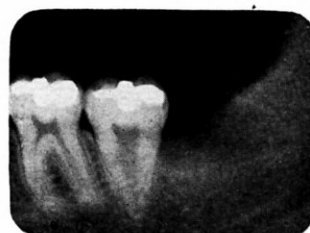7-B (b)

The upper portion of the crown and part of the distal root has been split and removed.



7-B (c)

The remaining half of the crown has been split and is loose in the crypt ready to be removed.



7-B (d)

The roots have been pulled forward into the space provided and removed. Note that no bone was removed.

## Analysis of the Potential Anatomic Problems Involved Preparatory to the Removal of Lower Impacted Third Molars

1. Relation of the tooth to the ramus of the mandible:
  - CLASS I Sufficient amount of space between the ramus and the distal of the second molar for the accommodation of the mesio-distal diameter of the crown of the third molar.
  - CLASS II The space between the ramus and the distal of the second molar less than the mesio-distal diameter of the crown of the third molar.
  - CLASS III All or most of the third molar within the ramus.
2. Relative depth of the third molar in bone:
  - POSITION A. The highest portion of the tooth on a level with or above the occlusal line.
  - POSITION B. The highest portion of the tooth below the occlusal line, but above the cervical line of the second molar.
  - POSITION C. The highest portion of the tooth on a level with or below the cervical line of the second molar.
3. The position of the tooth in relation to the long axis of the second molar:
  - (1) Vertical
  - (2) Horizontal
  - (3) Inverted
  - (4) Mesio-angular
  - (5) Disto-angular

These may also occur in

  - a. Buccal deflection
  - b. Lingual deflection
  - c. Torsion
4. Complications:
  - (1) Abnormal root curvature
  - (2) Hypercementosis
  - (3) Proximity to the mandibular canal
  - (4) Bone density
  - (5) Adipose tissue
  - (6) Lack of accessibility
  - (7) Inflexibility of the muscles of the mouth

(continued from page 330)

that is needed. (The recently developed engine chisels are especially effective.)

3. The split portion is now removed. In some cases it is necessary to remove a small section of bone on the distal to permit the removal of the split piece. In vertical and mesio-angular impactions all that remains to be done is to insert a small lever from the buccal and rotate the tooth back into the space provided by the removal of the split piece. In horizontal impactions it is frequently necessary to separate the remaining half of the crown from the roots at the neck. This is accomplished by drilling one or two holes in the crown and then splitting with a lever or chisel.

4. The remainder of the crown is then lifted out and the roots brought

forward into the space formerly occupied by the crown.

The advantages of this method of procedure are obvious:

1. Incisions are less extensive since no work is done distally to the crown of the tooth.

2. Bone cutting is eliminated or materially reduced.

3. Injury to surrounding tissues, and especially to the mandibular nerve, is avoided as forced elevations are unnecessary.

4. The operating time can be reduced 50 per cent, and the reduction in swelling and the almost complete absence of trismus will make the time spent in developing such a technique well worth while. Our results in employing this method have been highly gratifying.

Hume-Mansur Building.

## LETTERS TO THE EDITOR

### A NEW IDEA FOR DENTAL SERVICE FOR CHILDREN

"By the use of an inexpensive motion picture projector, I have eliminated nine-tenths of the various difficulties usually encountered in the treatment of child patients. In fact, a visit to the dentist has become a treat to these little people, and most of them request that the 'movies' be turned on as soon as they are placed in the chair.

"The projector is placed on an accessory table to the rear and left of the patient so that it does not interfere in any way with my operations from the right of the chair. The table is on castors so that it may be moved to various distances from the screen. I usually find that on a bright day it will be necessary to move the projector closer to the chair and screen, necessarily making a smaller but brighter image.

The chief difficulty was in eliminating as much light as possible from the screen surface. This was solved by constructing a shadow box from a cardboard carton 15 by 15 feet square and about 2 feet in length. The entire inside and outside were coated with dull black paint. A beaded glass screen 15 inches square was glued to the bottom of the carton and the entire shadow box placed on a radiator in front of the chair. The picture, therefore, is projected over the left shoulder of the patient.

"Films were obtained from a rental library in Chicago and from various organizations that lend their films. A 400 foot reel is usually shown and the film lasts about 16 minutes which should be time enough for most operations. Mickey Mouse, Felix the Cat, and Charlie Chaplin—the children love them and a threat to shut off the movies dispels any opposition from them."—PHILIP WEINTRAUB, D.D.S., *Chicago*.

"Your periodical deserves a lot of credit. I am especially interested in the excellent series of plates on 'educating the patient.' Unfortunately, I missed the February, March and April, 1933 issues. Will you kindly send me those copies so that my library will be complete?

"Our own beloved Dr. Prinz from U. of P. has recommended your magazine as a means of keeping abreast of modern dental achievements."—GEORGE J. PARKER, D.D.S., *Bronx, N. Y.*

"I want to congratulate you upon the sheer magnificence of your publication. It is unquestionably unique in its field."—DR. HAROLD R. JACOBS, *Rockaway Beach, N. Y.*

"Since I have only received two copies of THE DENTAL DIGEST, I find that I have missed something which I should have been getting for some time past and that is that I would like the issues of THE DIGEST of February and March of this year. As a matter of fact you can start my subscription from the February number."—DR. R. C. ALLEN, *Mitchell, Nebr.*

"I have to reiterate that I still enjoy reading your most up-to-date journal and wish you all success."—DR. J. BROWN DAVIES, *Inverness, Scotland*.